# I. Biology of Male Reproductive System

**Click here for Male Reproductive system video**

**The male reproductive system** is also under the influence of hormones and is responsible for producing sperm. The male reproductive system is both internal and external.

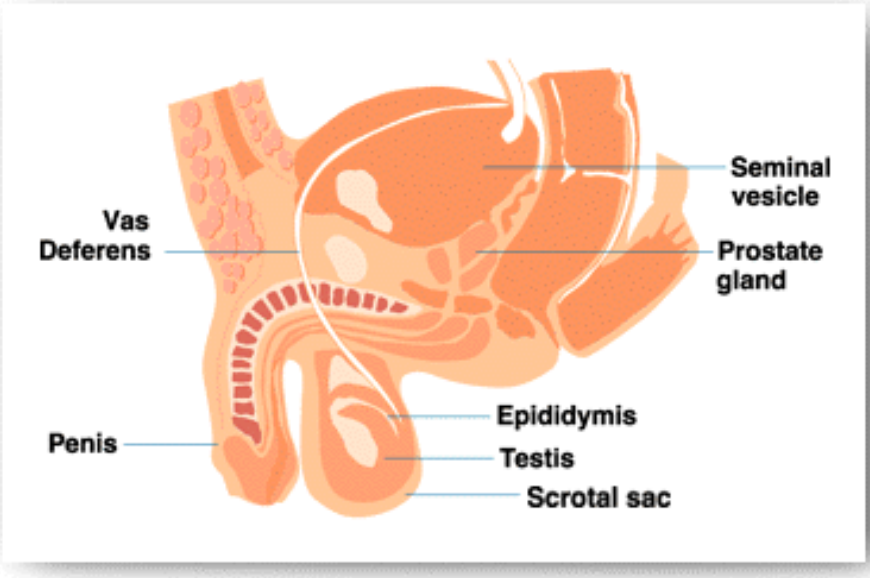


The testes are located within the scrotal sac, the pouch of skin located below the man's penis. These are the two organs that produce both sperm and testosterone, the male hormone that helps maintain the male sexual characteristics. As sperm are produced, they pass from the testes through the coiled channels of the epididymis, an organ that stores and nourishes them as they mature.

Once sperm are completely mature, they move into the vas deferens. This tubal structure connects the epididymis with the seminal vesicles, the two pouchlike glands that provide storage for the mature sperm. The entire process of sperm formation to maturation takes about 72 days.

When a man ejaculates (or expels the fluid from his penis) during intercourse, sperm from the seminal vesicles combine with a thick fluid from the prostate gland to create semen. This fluid (or ejaculate) is deposited into the woman's vagina.

**SPERM DEVELOPMENT**

**The development of normal,** mature sperm is key in establishing male fertility and involves an interplay of several factors:

- An exchange of hormonal messages between the brain and the testicles
- A secretion of necessary reproductive hormones (testosterone) by Leydig cells and normal sperm development within Sertoli cells
- Normal transport of developing sperm from testicles to epididymis to vas deferens

The production of sperm is primarily regulated by three hormones:

- FSH
- LH
- Testosterone

In the male, pituitary hormones are responsible for maintaining the sperm production process. The pituitary gland, which is located at the base of the brain, secretes FSH and LH, the same hormones necessary for regulating the female's reproductive functions. FSH is responsible for stimulating sperm production in the testicles. LH stimulates the production of testosterone. Under the influence of Sertoli cells and specific hormones, immature sperm cells develop through several stages and eventually become mature sperm cells, called spermatozoa. Spermatozoa are not yet motile. They must pass through the epididymis, where after 18 to 24 hours, they gain motility (movement). After acquiring the ability to move, mature sperm are stored in the vas deferens until ejaculation.

---

## II. Gray's Anatomy: The Male Genital Organs

**(Organa Genitalia Virilia)** *1*

The male genitals include the **testes,** the **ductus deferentes,** the **vesiculæ seminales,** the **ejaculatory ducts,** and the **penis,** together with the following accessory structures, viz., the **prostate** and the **bulbourethral glands.**

**1. The Testes and their Coverings (Figs. 1143, 1144, 1145)**—The **testes** are two glandular organs, which secrete the semen; they are suspended in the scrotum by the spermatic cords. At an early period of fetal life the testes are contained in the abdominal cavity, behind the peritoneum. Before birth they descend to the inguinal canal, along which they pass with the spermatic cord, and, emerging at the subcutaneous inguinal ring, they descend into the scrotum, becoming invested in their course by coverings derived from the serous, muscular, and fibrous layers of the abdominal parietes, as well as by the scrotum. *2*

The **coverings of the testes** are, the *3*

| | | |
|---|---|---|
| Skin | Scrotum. | Cremaster. |
| Dartos tunic | | Infundibuliform fascia. |
| Intercrural fascia. | | Tunica vaginalis. |

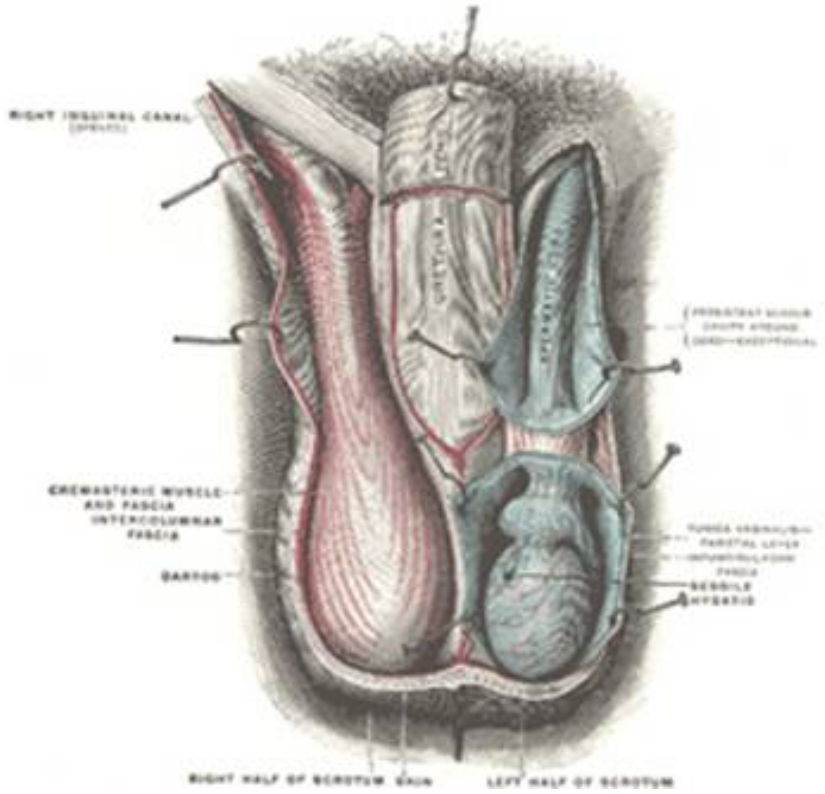


FIG. 1143– The scrotum. On the left side the cavity of the tunica vaginalis has been opened; on the right side only the layers superficial to the Cremaster have been removed. (Testut.) (Click here to See enlarged image)

The **Scrotum** is a cutaneous pouch which contains the testes and parts of the spermatic cords. It is divided on its surface into two lateral portions by a ridge or **raphé,** which is continued forward to the under surface of the penis, and backward, along the middle line of the perineum to the anus. Of these two lateral portions the left hangs lower than the right, to correspond with the greater length of the left spermatic cord. Its external aspect varies under different circumstances: thus, under the influence of warmth, and in old and debilitated persons, it becomes elongated and flaccid; but, under the influence of cold, and in the young and robust, it is short, corrugated, and closely applied to the testes. *4*

The scrotum consists of two layers, the **integument** and the **dartos tunic.** *5*

The **Integument** is very thin, of a brownish color, and generally thrown into folds or rugæ. It is provided with sebaceous follicles, the secretion of which has a peculiar odor, and is beset with thinly scattered, crisp hairs, the roots of which are seen through the skin. *6*

The **Dartos Tunic** (*tunica dartos*) is a thin layer of non-striped muscular fibers, continuous, around the base of the scrotum, with the two layers of the superficial fascia of the groin and the perineum; it sends inward a septum, which divides the scrotal pouch into two cavities for the testes, and extends between the raphé and the under surface of the penis, as far as its root. *7*

FIG. 1144– The scrotum. The penis has been turned upward, and the anterior wall of the scrotum has been removed. On the right side, the spermatic cord, the infundibuliform fascia, and the Cremaster muscle are displayed; on the left side, the infundibuliform fascia has been divided by a longitudinal incision passing along the front of the cord and the testicle, and a portion of the parietal layer of the tunica vaginalis has been removed to display the testicle and a portion of the head of the epididymis, which are covered by the visceral layer of the tunica vaginalis. (Toldt.) (Click here to See enlarged image)

The dartos tunic is closely united to the skin externally, but connected with the subjacent parts by delicate areolar tissue, upon which it glides with the greatest facility. *8*

The **Intercrural Fascia** (*intercolumnar or external spermatic fascia*) is a thin membrane, prolonged downward around the surface of the cord and testis (see page 411). It is separated from the dartos tunic by loose areolar tissue. *9*

The **Cremaster** consists of scattered bundles of muscular fibers connected together into a continuous covering by intermediate areolar tissue (see page 414). *10*

The **Infundibuliform Fascia** (*tunica vaginalis communis* [*testis et funiculi spermatici*]) is a thin layer, which loosely invests the cord; it is a continuation downward of the transversalis fascia (see page 418). *11*

The **Tunica Vaginalis** is described with the testes. *12*

FIG. 1145– Transverse section through the left side of the scrotum and the left testis. The sac of the tunica vaginalis is represented in a distended condition. (Diagrammatic.) (Delépine.) (Click here to See enlarged image)

**Vessels and Nerves.**—The **arteries** supplying the coverings of the testes are: the superficial and deep external pudendal branches of the femoral, the superficial perineal branch of the internal pudendal, and the cremasteric branch from the inferior epigastric. The **veins** follow the course of the corresponding arteries. The **lymphatics** end in the inguinal lymph glands. The **nerves** are the ilioinguinal and lumboinguinal branches of the lumbar plexus, the two superficial perineal branches of the internal pudendal nerve, and the pudendal branch of the posterior femoral cutaneous nerve. *13*

The **Inguinal Canal** (*canalis inguinalis*) is described on page 418. *14*

The **Spermatic Cord** (*funiculus spermaticus*) (Fig. 1146) extends from the abdominal inguinal ring, where the structures of which it is composed converge, to the back part of the testis. In the abdominal wall the cord passes obliquely along the inguinal canal, lying at first beneath the Obliquus internus, and upon the fascia transversalis; but nearer the pubis, it rests upon the inguinal and lacunar ligaments, having the aponeurosis of the Obliquus externus in front of it, and the inguinal falx behind it. It then escapes at the subcutaneous ring, and descends nearly vertically into the scrotum. The left cord is rather longer than the right, consequently the left testis hangs somewhat lower than its fellow. *15*

**Structure of the Spermatic Cord.**—The spermatic cord is composed of arteries, veins, lymphatics, nerves, and the excretory duct of the testis. These structures are connected together by areolar tissue, and invested by the layers brought down by the testis in its descent. 16

The **arteries of the cord** are: the internal and external spermatics; and the artery to the ductus deferens. 17

The *internal spermatic artery*, a branch of the abdominal aorta, escapes from the abdomen at the abdominal inguinal ring, and accompanies the other constituents of the spermatic cord along the inguinal canal and through the subcutaneous inguinal ring into the scrotum. It then descends to the testis, and, becoming tortuous, divides into several branches, two or three of which accompany the ductus deferens and supply the epididymis, anastomosing with the artery of the ductus deferens: the others supply the substance of the testis. 18

The *external spermatic artery* is a branch of the inferior epigastric artery. It accompanies the spermatic cord and supplies the coverings of the cord, anastomosing with the internal spermatic artery. 19

The *artery of the ductus deferens*, a branch of the superior vesical, is a long, slender vessel, which accompanies the ductus deferens, ramifying upon its coats, and anastomosing with the internal spermatic artery near the testis. 20

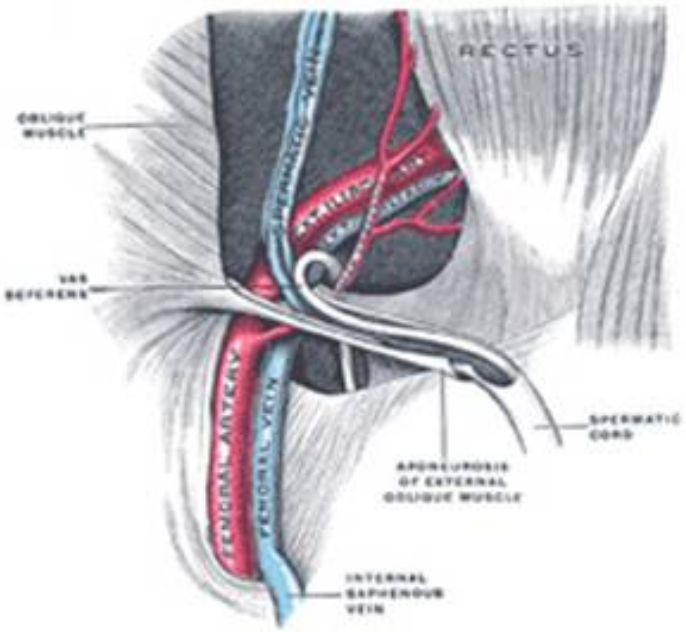


FIG. 1146– The spermatic cord in the inguinal canal. (Poirier and Charpy.) (See enlarged image)

The **spermatic veins** (Fig. 1147) emerge from the back of the testis, and receive tributaries from the epididymis: they unite and form a convoluted plexus, the **plexus pampiniformis,** which forms the chief mass of the cord; the vessels composing this plexus are very numerous, and ascend along the cord in front of the ductus deferens; below the subcutaneous inguinal ring they unite to form three or four veins, which pass along the inguinal canal, and, entering the abdomen through the abdominal inguinal ring, coalesce to form two veins. These again unite to form a single vein, which opens on the right side into the inferior vena cava, at an acute angle, and on the left side into the left renal vein, at a right angle. 21

The **lymphatic vessels** are described on page 713. 22

The **nerves** are the spermatic plexus from the sympathetic, joined by filaments from the pelvic plexus which accompany the artery of the ductus deferens. 23

The scrotum forms an admirable covering for the protection of the testes. These bodies, lying suspended and loose in the cavity of the scrotum and surrounded by serous membrane, are capable of great mobility, and can therefore easily slip about within the scrotum and thus avoid injuries from blows or squeezes. The skin of the scrotum is very elastic and capable of great distension, and on account of the looseness and amount of subcutaneous tissue, the scrotum becomes greatly enlarged in cases of edema, to which this part is especially liable as a result of its dependent position. 24

The **Testes** are suspended in the scrotum by the spermatic cords, the left testis hanging somewhat lower than its fellow. The average dimensions of the testis are from 4 to 5 cm. in length, 2.5 cm. in breadth, and 3 cm. in the antero-posterior diameter; its weight varies from 10.5 to 14 gm. Each testis is of an oval form (Fig. 1148), compressed laterally, and having an oblique position in the scrotum; the upper extremity is directed forward and a little lateralward; the lower, backward and a little medialward; the anterior convex border looks forward and downward, the posterior or straight border, to which the cord is attached, backward and upward. 25

The anterior border and lateral surfaces, as well as both extremities of the organ, are convex, free, smooth, and invested by the visceral layer of the tunica vaginalis. The posterior border, to which the cord is attached, receives only a partial investment from that membrane. Lying upon the lateral edge of this posterior border is a long, narrow, fiattened body, named the **epididymis.** 26

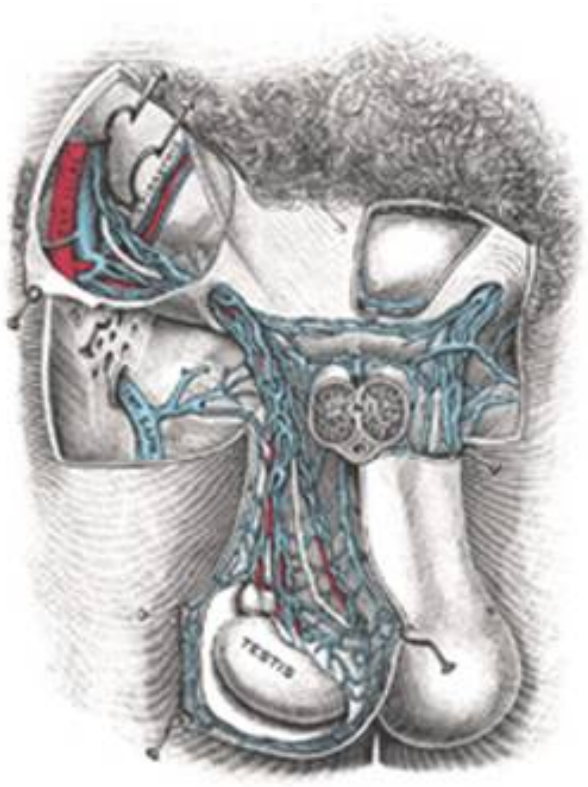


FIG. 1147– Spermatic veins. (Testut.) (See enlarged image)

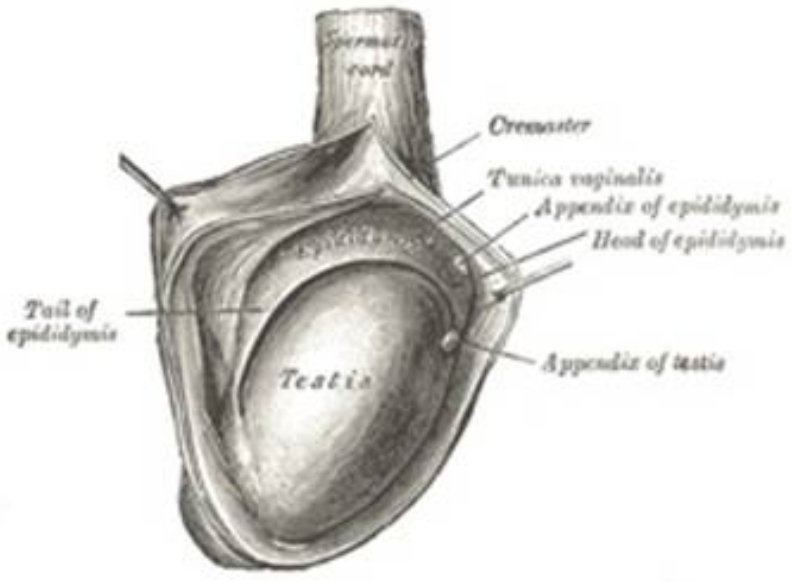


FIG. 1148– The right testis, exposed by laying open the tunica vaginalis. (See enlarged image)

The **epididymis** consists of a central portion or **body;** an upper enlarged extremity, the **head** (*globus major*); and a lower pointed extremity, the **tail** (*globus minor*), which is continuous with the ductus deferens, the **duct of the testis.** The head is intimately connected with the upper end of the testis by means of the efferent ductules of the gland; the tail is connected with the lower end by cellular tissue, and a reflection of the tunica vaginalis. The lateral surface, head and tail of the epididymis are free and covered by the serous membrane; the body is also completely invested by it, excepting along its posterior border; while between the body and the testis is a pouch, named the **sinus of the epididymis** (*digital fossa*). The epididymis is connected to the back of the testis by a fold of the serous membrane. 27

**Appendages of the Testis and Epididymis.**—On the upper extremity of the testis, just beneath the head of the epididymis, is a minute oval, sessile body, the **appendix of the testis** (*hydatid of Morgagni*); it is the remnant of the upper end of the Müllerian duct. On the head of the epididymis is a second small stalked appendage (sometimes duplicated); it is named the **appendix of the epididymis** (*pedunculated hydatid*), and is usually regarded as a detached efferent duct. 28

The testis is invested by three tunics: the **tunica vaginalis, tunica albuginea,** and **tunica vasculosa.** 29

The **Tunica Vaginalis** (*tunica vaginalis propria testis*) is the serous covering of the testis. It is a pouch of serous membrane, derived from the saccus vaginalis of the peritoneum, which in the fetus preceded the descent of the testis from the abdomen into the scrotum. After its descent, that portion of the pouch which extends from the abdominal inguinal ring to near the upper part of the gland becomes obliterated; the lower portion remains as a shut sac, which invests the surface of the testis, and is reflected on to the internal surface of the scrotum; hence it may be described as consisting of a **visceral** and a **parietal lamina.** 30

The **visceral lamina** (*lamina visceralis*) covers the greater part of the testis and epididymis, connecting the latter to the testis by means of a distinct fold. From the posterior border of the gland it is reflected on to the internal surface of the scrotum. 31

The **parietal lamina** (*lamina parietalis*) is far more extensive than the visceral, extending upward for some distance in front and on the medial side of the cord, and reaching below the testis. The inner surface of the tunica vaginalis is smooth, and covered by a layer of endothelial cells. The interval between the visceral and parietal laminæ constitutes the cavity of the tunica vaginalis. *32*

The obliterated portion of the saccus vaginalis may generally be seen as a fibrocellular thread lying in the loose areolar tissue around the spermatic cord; sometimes this may be traced as a distinct band from the upper end of the inguinal canal, where it is connected with the peritoneum, down to the tunica vaginalis; sometimes it gradually becomes lost on the spermatic cord. Occasionally no trace of it can be detected. In some cases it happens that the pouch of peritoneum does not become obliterated, but the sac of the peritoneum communicates with the tunica vaginalis. This may give rise to one of the varieties of oblique inguinal hernia (page 1187). In other cases the pouch may contract, but not become entirely obliterated; it then forms a minute canal leading from the peritoneum to the tunica vaginalis. *33*

The **Tunica Albuginea** is the fibrous covering of the testis. It is a dense membrane, of a bluish-white color, composed of bundles of white fibrous tissue which interlace in every direction. It is covered by the tunica vaginalis, except at the points of attachment of the epididymis to the testis, and along its posterior border, where the spermatic vessels enter the gland. It is applied to the tunica vasculosa over the glandular substance of the testis, and, at its posterior border, is reflected into the interior of the gland, forming an incomplete vertical septum, called the **mediastinum testis** (*corpus Highmori*). *34*

The **mediastinum testis** extends from the upper to near the lower extremity of the gland, and is wider above than below. From its front and sides numerous imperfect septa (*trabeculæ*) are given off, which radiate toward the surface of the organ, and are attached to the tunica albuginea. They divide the interior of the organ into a number of incomplete spaces which are somewhat cone-shaped, being broad at their bases at the surface of the gland, and becoming narrower as they converge to the mediastinum. The mediastinum supports the vessels and duct of the testis in their passage to and from the substance of the gland. *35*

The **Tunica Vasculosa** is the vascular layer of the testis, consisting of a plexus of bloodvessels, held together by delicate areolar tissue. It clothes the inner surface of the tunica albuginea and the different septa in the interior of the gland, and therefore forms an internal investment to all the spaces of which the gland is composed. *36*

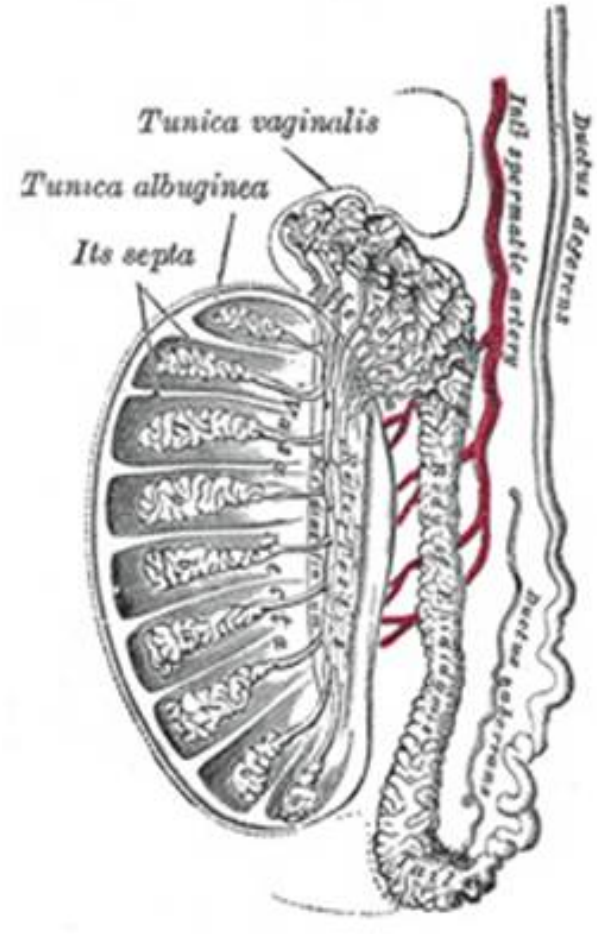


FIG. 1149– Vertical section of the testis, to show the arrangement of the ducts. (See enlarged image)

**Structure.**—The glandular structure of the testis consists of numerous lobules. Their number, in a single testis, is estimated by Berres at 250, and by Krause at 400. They differ in size according to their position, those in the middle of the gland being larger and longer. The lobules (Fig. 1149) are conical in shape, the base being directed toward the circumference of the organ, the apex toward the mediastinum. Each lobule is contained in one of the intervals between the fibrous septa which extend between the mediastinum testis and the tunica albuginea, and consists of from one to three, or more, minute convoluted tubes, the **tubuli seminiferi.** The tubules may be separately unravelled, by careful dissection under water, and may be seen to commence either by free cecal ends or by anastomotic loops. They are supported by loose connective tissue which contains here and there groups of "interstitial cells" containing yellow pigment granules. The total number of tubules is estimated by Lauth at 840, and the average length of each is 70 to 80 cm. Their diameter varies from 0.12 to 0.3 mm. The tubules are pale in color in early life, but in old age they acquire a deep yellow tinge from containing much fatty matter. Each tubule consists of a basement layer formed of laminated connective tissue containing numerous elastic fibers with flattened cells between the layers and covered externally by a layer of flattened epithelioid cells. Within the basement membrane are epithelial cells arranged in several irregular layers, which are not always clearly separated, but which may be arranged in three different groups (Fig. 1150). Among these cells may be seen the **spermatozoa** in different stages of development. (1) Lining the basement membrane and forming the

37

outer zone is a layer of cubical cells, with small nuclei; some of these enlarge to become **spermatogonia.** The nuclei of some of the spermatogonia may be seen to be in process of indirect division (*karyokineses*, page 37), and in consequence of this daughter cells are formed, which constitute the second zone. (2) Within this first layer is to be seen a number of larger polyhedral cells, with clear nuclei, arranged in two or three layers; these are the **intermediate cells** or **spermatocytes.** Most of these cells are in a condition of karyokinetic division, and the cells which result from this division form those of the next layer, the **spermatoblasts** or **spermatids.** (3) The third layer of cells consists of the spermatoblasts or spermatids, and each of these, without further subdivision, becomes a **spermatozoön.** The spermatids are small polyhedral cells, the nucleus of each of which contains half the usual number of chromosomes. In addition to these three layers of cells others are seen, which are termed the **supporting cells** (*cells of Sertoli*). They are elongated and columnar, and project inward from the basement membrane toward the lumen of the tube. As development of the spermatozoa proceeds the latter group themselves around the inner extremities of the supporting cells. The nuclear portion of the spermatid, which is partly imbedded in the supporting cell, is differentiated to form the head of the spermatozoön, while part of the cell protoplasm forms the middle piece and the tail is produced by an outgrowth from the double centriole of the cell. Ultimately the heads are liberated and the spermatozoa are set free. The structure of the spermatozoa is described on pages 42, 43.

In the apices of the lobules, the tubules become less convoluted, assume a nearly straight course, and unite together to form from twenty to thirty larger ducts, of about 0.5 mm. in diameter, and these, from their straight course, are called **tubuli recti** (Fig. 1149). *38*

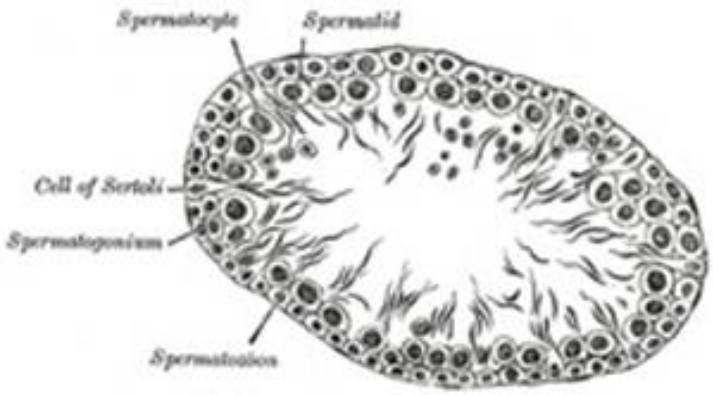


FIG. 1150– Transverse section of a tubule of the testis of a rat. X 250. (See enlarged image)

The **tubuli recti** enter the fibrous tissue of the mediastinum, and pass upward and backward, forming, in their ascent, a close net-work of anastomosing tubes which are merely channels in the fibrous stroma, lined by flattened epithelium, and having no proper walls; this constitutes the **rete testis.** At the upper end of the mediastinum, the vessels of the rete testis terminate in from twelve to fifteen or twenty ducts, the **ductuli efferentes;** they perforate the tunica albuginea, and carry the seminal fluid from the testis to the epididymis. Their course is at first straight; they then become enlarged, and exceedingly convoluted, and form a series of conical masses, the **coni vasculosi,** which together constitute the head of the epididymis. Each cone consists of a single convoluted duct, from 15 to 20 cm. in length, the diameter of which gradually decreases from the testis to the epididymis. Opposite the bases of the cones the efferent vessels open at narrow intervals into a single duct, which constitutes, by its complex convolutions, the body and tail of the epididymis. When the convolutions of this tube are unravelled, it measures upward of 6 meters in length; it increases in diameter and thickness as it approaches the ductus deferens. The convolutions are held together by fine areolar tissue, and by bands of fibrous tissue. *39*

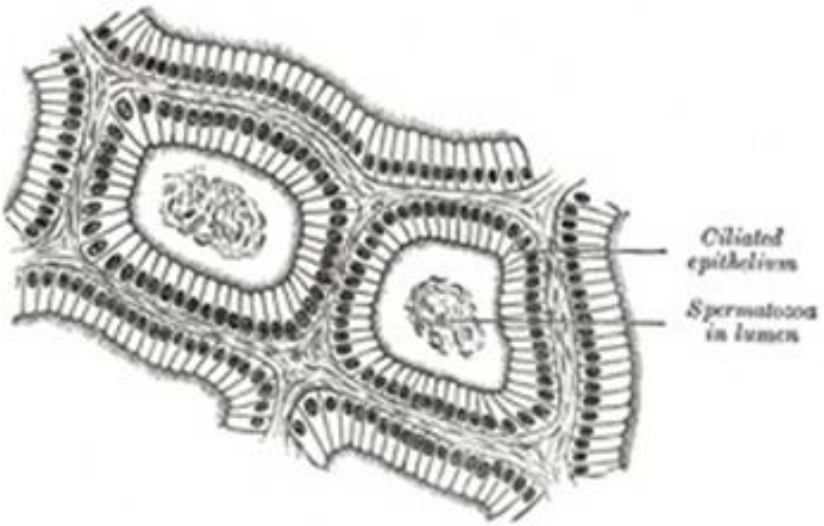


FIG. 1151– Section of epididymis of guinea-pig. X 255. (See enlarged image)

The tubuli recti have very thin walls; like the channels of the rete testis they are lined by a single layer of flattened epithelium. The ductuli efferentes and the tube of the epididymis have walls of considerable thickness, on account of the presence in them of muscular tissue, which is principally arranged in a circular manner. These tubes are lined by columnar ciliated epithelium (Fig. 1151). *40*

**Peculiarities.**—The testis, developed in the lumbar region, may be arrested or delayed in its transit to the scrotum (*cryptorchism*). It may be retained in the abdomen; or it may be arrested at the abdominal inguinal ring, or in the inguinal canal; or it may just pass out of the subcutaneous inguinal ring without finding its way to the bottom of the scrotum. When retained in the abdomen it gives rise to no symptoms, other than the absence of the testis from the scrotum; but when it is retained in the inguinal canal it is subjected to pressure and may become inflamed and painful. The retained testis is probably functionally useless; so that a man in whom both testes are retained (*anorchism*) is sterile, though he may not be impotent. The absence of one testis is termed *monorchism.* When a testis is retained in the inguinal canal it is often complicated with a congenital hernia, the funicular process of the peritoneum not being obliterated. In addition to the cases above described, where there is some arrest in the descent of the testis, this organ may descend through the inguinal canal, but may miss the scrotum and assume some abnormal position. The most common form is where the testis, emerging at the subcutaneous inguinal ring, slips down between the scrotum and thigh and comes to rest in the perineum. This is known as *perineal ectopia testis.* With each variety of abnormality in the position of the testis, it is very common to find concurrently a congenital hernia, or, if a hernia be not actually present, the funicular process is usually patent, and almost invariably so if the testis is in the inguinal canal. *41*

The testis, finally reaching the scrotum, may occupy an abnormal position in it. It may be inverted, so that its posterior or attached border is directed forward and the tunica vaginalis is situated behind. *42*

Fluid collections of a serous character are very frequently found in the scrotum. To these the term *hydrocele* is applied. The most common form is the ordinary *vaginal hydrocele,* in which the fluid is contained in the sac of the tunica vaginalis, which is separated, in its normal condition, from the peritoneal cavity by the whole extent of the inguinal canal. In another form, the *congenital hydrocele,* the fluid is in the sac of the tunica vaginalis, but this cavity communicates with the general peritoneal cavity, its tubular process remaining pervious. A third variety known as an *infantile hydrocele,* occurs in those cases where the tubular process becomes obliterated only at its upper part, at or near the abdominal inguinal ring. It resembles the vaginal hydrocele, except as regards its shape, the collection of fluid extending up the cord into the inguinal canal. Fourthly, the funicular process may become obliterated both at the abdominal inguinal ring and above the epididymis, leaving a central unobliterated portion, which may become distended with fluid, giving rise to a condition known as the *encysted hydrocele of the cord.*

## III. External Male Genitals

The external male genitals consist of the penis and the scrotum.

The **penis** is a cylindrical structure with the capacity to be flaccid or erect. It is very sensitive to stimulation, and it is the organ that penetrates the vagina or anus during penetrative sex. The head of the penis, the ***glans*** (*glans penis*), includes the most highly innervated part of the penis and is covered by the foreskin in men who are not circumcised. The penis provides passage for both urine and semen.

The **scrotum** is a pouch of skin hanging directly under the penis that contains the testes. The

scrotum protects the testes and maintains the temperature necessary for the production of sperm by the testes.

## Internal male genitals

The internal male genitals are the testes, the epididymides, the vasa deferentia, the seminal vesicles, the prostate gland, and the Cowper's glands.

The **testes**, the paired, oval-shaped organs that produce sperm and male sex hormones, are located in the scrotum. They are highly innervated and sensitive to touch and pressure. The testes produce ***testosterone***, which is responsible for the development of male sexual characteristics and sex drive (***libido***).

The **epididymides** are the two highly coiled tubes against the posterior side of the testes where sperm mature and are stored until they are released during ejaculation.

The **vasa deferentia** (singular, vas deferens) are the paired tubes that carry the mature sperm from the epididymides to the urethra.

The **seminal vesicles** are a pair of glandular sacs that secrete about 60% of the fluid that makes up the semen in which sperm are transported. Seminal fluid provides nourishment for sperm.

The **prostate gland** is a walnut-sized glandular structure that secretes about 30% of the fluid that makes up semen. The alkaline quality of the fluid neutralizes the acidic environment of the male and female reproductive tracts. A muscle at the bottom of the prostate gland keeps the sperm out of the urethra until ejaculation begins. The prostate gland is very sensitive to stimulation and can be a source of sexual pleasure for some men.

**Cowper's glands** are two pea-sized glands at the base of the penis under the prostate that secrete a clear alkaline fluid into the urethra during sexual arousal and before orgasm and ejaculation. These glands produce mucoid, pre-ejaculatory fluid in the urethra that acts as a lubricant for the sperm and coats the urethra as semen flows out of the penis.

---

---

## IV. Education on Fore-Skin

A surprising number of people in the US have never seen an intact penis. They have no idea what a foreskin is, what it does, what it looks like, or what it's good for. This is especially true for the older generations since the circumcision rate in the US was once as high as 95%. It is now dropped to 60% for the US as a whole and 30% in the western states. In most other western countries, the infant circumcision rate is near zero.

Many doctors in the US have no idea what a foreskin does or what it is good for. These doctors know only about the "problems" guys can have with their foreskins and know of no solutions other than circumcision. No anatomy textbook that I've ever seen has an accurate diagram of what the foreskin is or how it works, although I havn't looked lately (if there is one, I'd like to know). The following pictures are intended show a lot more.

**Preventing Circumcision**
I hope that once people are educated about the male anatomy, they will stop circumcising their male infants.

**Foreskin Restoration**
This information is also meant to support guys like me, who are circumcised and interested in or are in the process of foreskin restoration. This is meant to help guys who are circumcised understand how their bodies have been changed by circumcision and what they can do about it.

I'm really putting this up because so many people have been asking the question. So here it goes...

---

# The foreskin - What it does

The foreskin performs several important functions. Most of these functions center on making sex more enjoyable, not only for just one, but for both partners.

Protection
Makes sex feel better
Lubricates during intercourse
Lubricates during masturbation
Reduces the drop insensitivity through age
Allows the erection to grow
Increases sensitivity slowing intercourse

# The foreskin - What it is

I

First what the foreskin is not: The foreskin is not a flap of skin on the end of the penis. This kind of terminology has been used to imply that the foreskin is something redundant with no real function, that can easily be removed with no consequence. This is not the case.

The foreskin is special in that it is not directly attached as most skin is. It is free to slide up and down the shaft of the penis with almost no friction. The foreskin can be thought of as a continuation of the tube of skin that covers the shaft of the penis, but much longer. This tube of skin is firmly attached only at the base of the penis and at the head of the penis. In between the points of attachment this tube of skin has the special property that easily slides on the shaft of the penis rather than being firmly connected as most skin is. The foreskin's length and the fact that it is unattached in the middle allows it to slide up and down the shaft of the penis and roll in on itself over the head of the penis (see diagram below).

The foreskin is long enough so that it continues down the shaft of the penis and rolls in on itself over the head of the penis. For those of you who are only familiar with circumcised penises, that means that an intact penis has two to three **times** as much skin that a circumcised penis.

A foreskin is long. An intact penis has two to three times the length of skin that a circumcised penis has. When flaccid, most of this length is taken up in the double fold of skin covering the head of the penis. When erect the foreskin can roll back to allow the penis to lengthen while still allowing the skin on the shaft of the penis to remain loose. The foreskin is often long enough to cover the head of the penis while erect.

The foreskin is extremely sensitive. It is filled with nerve endings called stretch receptors that fire when they are stretched, rolled, or massaged.

**An intact penis, erect with the foreskin being retracted**

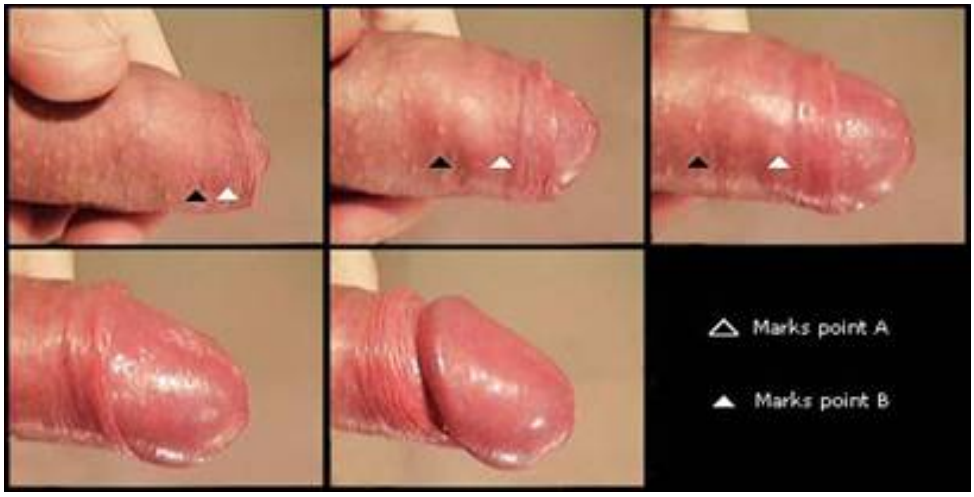

These pictures show the skin mobility for an intact penis, while erect. The movement of skin marked by point A is several inches back and forth. The foreskin also stretches a lot when pulled back. Notice how point B moves and how the end of the foreskin widens to accommodate the head of the penis. With the foreskin pulled back, it looks a lot like a circumcised penis. Note the color and texture of the head of the penis. It is soft and sensitive like the inside of the lip or the inside of the eyelid

For more pictures like these see Penile anatomy - Intact vs. Circumcised from Chymmylt's Foreskin Restoration Site.

**Things that are not obvious from these pictures:**
The stretching and rolling action shown in the above pictures are very important. The foreskin is filled with nerve endings called stretch receptors. These nerve endings fire when they are stretched, rolled, or massaged. The only purpose of these nerve endings is to make sex more enjoyable. The stretch receptors are unlike the nerve endings in the head of the penis which are very sensitive to friction but can be so sensitive that the sensation can be irritating or painful. The nerve endings in the head of the penis tend to trigger orgasm much more than the nerve endings in the foreskin.

The head of the penis has no skin. This may be a surprise to those of you who are familiar only with circumcised penises. The head of the penis is actually covered by a very thin moist mucus membrane, very much like the inside of the lip or the inside of the eyelid. The head of the penis is not meant to be exposed to the elements such as friction against clothing, friction during sex, the sun's rays, or soap (in infants urine or feces). The head of the penis is supposed to be protected by the warm, moist coccoon that the foreskin creates. If the foreskin is remvoed, the mucus membrane of the penis thickens in response to the lack of protection. It may look like skin, but it is not.

The foreskin is lined with smoothe muscle fibers which contract to make the foreskin wrap snugly around the head of the penis. These muscle fibers can relax to permit the foreskin to be retracted.

Friction. There is no friction.

**An intact penis, erect with the foreskin being retracted, another view**

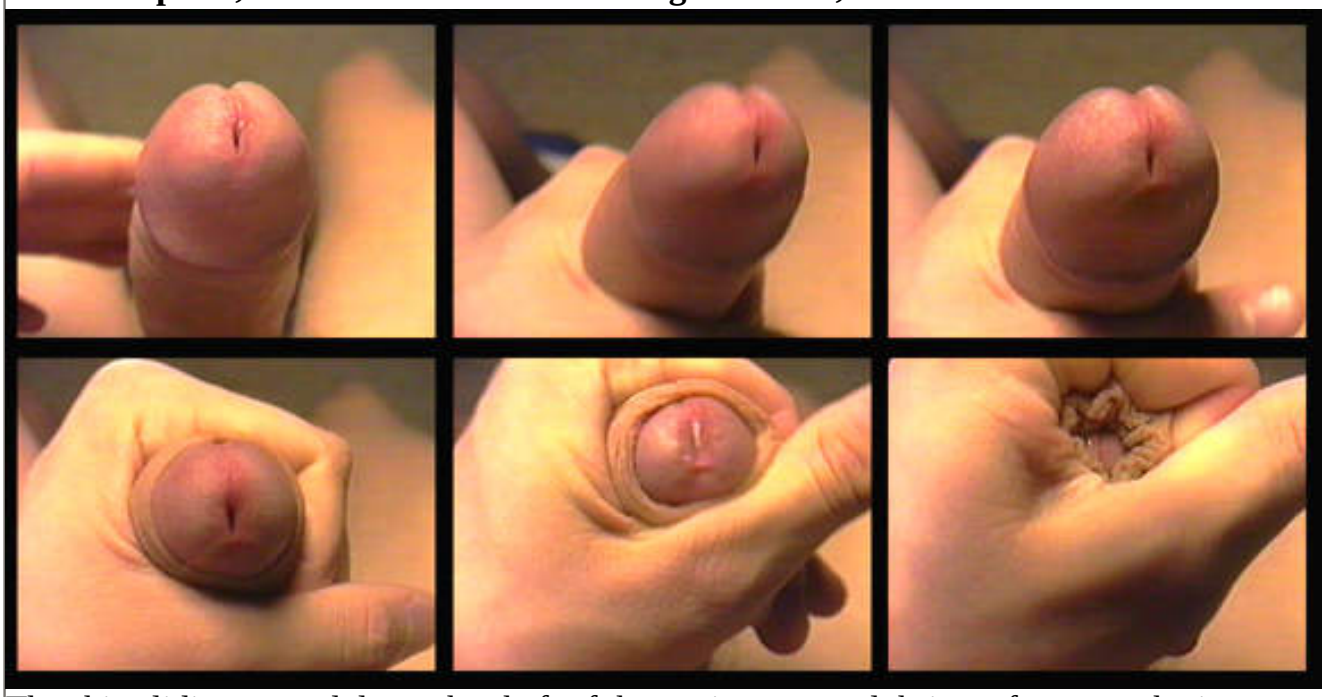

The skin sliding up and down the shaft of the penis acts as a lubricant for masturbation or intercourse. The head of the penis can be extremely sensitive to pain from friction. As the skin slides up and down the penis, the hand does not directly touch the head of the penis. The foreskin rolls over the head, allowing the hand to massage the head through two layers of skin to minimize any irritation from friction. See Anatomy of the Penis and Mechanics of Intercourse for more information.

**Anonymous photo taken from usenet news.**

**A view of the frenulum, foreskin retracted**

The frenulum is a Y shaped web of skin that connects the foreskin to the underside of the head of the penis. The frenulum is kind of like the web of skin under the tongue. This is the most sensitive part of the penis, containing a huge number of nerve endings. Circumcision usually removes all or most of the frenulum. For more information see The Effects of Circumcision by Glenn M.J. Epps' Circumcision Facts.

**Anonymous photo taken from usenet news.**

I

**An intact penis, erect with the foreskin covering and retracted**

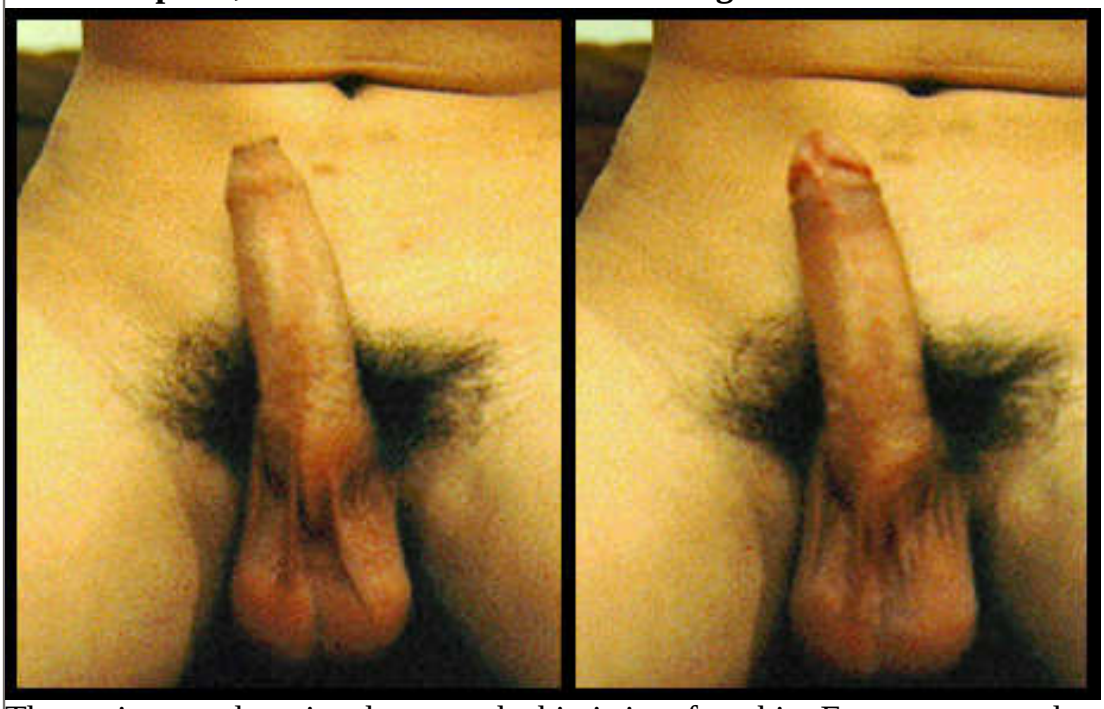

These pictures show just how much skin is in a foreskin. For many guys there is enough loose skin to allow the foreskin to cover the head of the penis while erect, even without something holding it in place. This amount of coverage can be helpful because nocturnal erections do not expose the head of the penis.

# V. PENIS ANATOMY

Although the penis is a rather ordinary, everyday organ (at least for about 50% of the population), it is surprising how little some people know about this part of the body.  In some animals, the penis is equipped with a small bone, not so in humans. In the adult male, the penis is about 2 to 3 inches long, although this can differ from day to day. When it is cold, the penis can withdraw into the fatty tissue overlying the pubic bone, which makes it seem shorter, especially in men with a lot of fat there. There is generally little variation in the 'real' length of the penis between different men; in some races it's somewhat longer, in others a bit shorter. During erection, the penile length varies between 6 and 8 inches.

Three major structures can be found in the penis: the urethra and two long cylinders, the erectile bodies.

I

The **urethra**, with a thick, spongy cylinder around it, is located below. The urethra is designed to conduct urine to the outside world, but can only be considered a tube when it does; after the urine is expelled, the elastic fibers in its wall make sure it collapses. The tube ends at the **glans** of the penis. The skin on the glans is very sensitive and is normally protected by the foreskin, which acts as a cover. The foreskin should be able to slide back and forth over the glans easily, although this is not always the case yet in children. To ease the sliding, small glands produce a kind of grease. When this area of the body is not cleaned regularly, the grease may become noticeable as *smegma*. In the middle of the lower part of the foreskin a small skin-slip can be found (Latin: *phrenulum*), running from the foreskin towards the opening of the urethra; the function of this slip of foreskin is unknown, but sometimes it can be painful during erections when it is too short.

The erectile bodies, long cylinders, that are located next to each other at the 'back' of the penis. They contain blood. During erection, the amount of blood inside the cylinders increases, because the inflow increases and the outflow of blood decreases; the cylinders are filled to the limit with blood and will stand upright, causing erection of the penis; it works just like those cylindric balloons. To ensure a good blood supply, several blood vessels run towards the erectile bodies and a dense web of small nerve fibers ensure the opening and closing of the right vessels during erection. Since there are no stiff structures, like bones or something similar, in the penis to give it rigidity, the penis is connected to the pubic bone by strong connective tissue; because of this, the erect penis is still rather stabile and pointing slightly upwards.

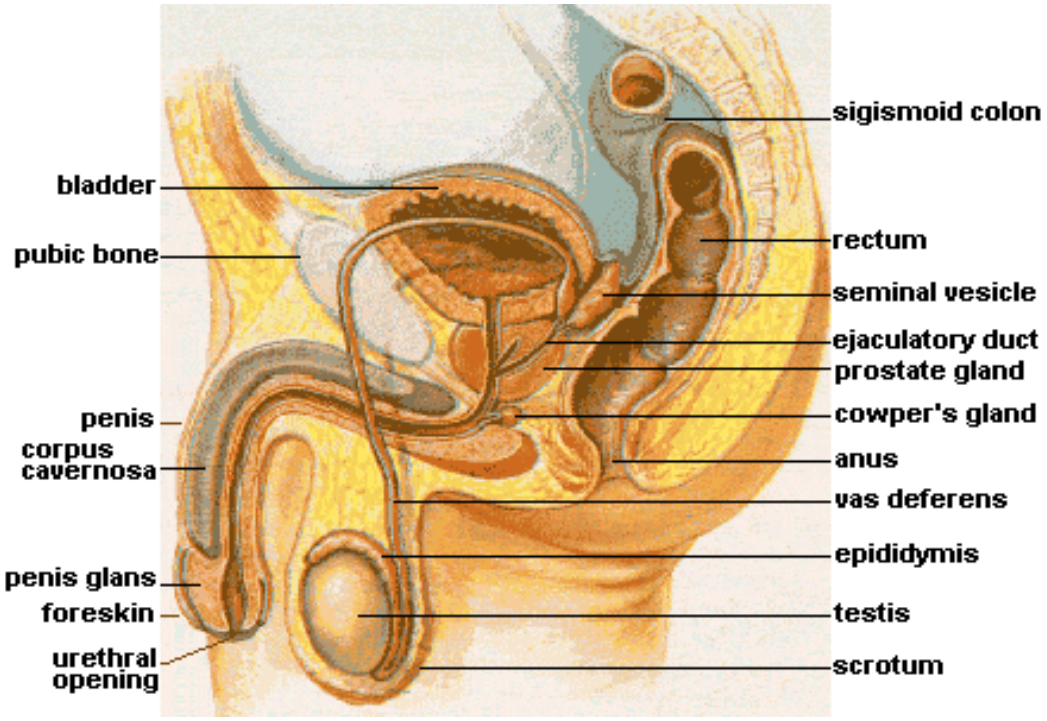

# FUNCTION

As you will undoubtedly know, the penis has three functions:

**Urinating**. This is a rather plain and simple function, where the penis serves as a extension of the urethra, thus enabling males to urinate easy anywhere they want without spilling any urine. In women this is more difficult and they will have to find a place to squat.

**Sexuality**. Simply put: an erect penis, i.e. a stiff one, can give pleasure. Having an erection is, however, a complicated procedure. In order to have an adequate erection three conditions must be fulfilled:

1. a certain amount of *lust* is required (Latin: *libido*)
2. a good *inflow and outflow of blood* is necessary
3. the management, i.e. the *nerve supply*, must be functioning properly

Getting and maintaining an erection is an automated process. It is mainly run from the nerve cells in the spinal chord. Of course, the owner of the penis does have some say in it, but only up to a limit, for instance by thinking or not thinking about someone/something (porn movies). The effects will generally be limited to erection or no erection; it is pretty hard to want to have *only a bit* of an erection. To show that the erection is governed by the spinal chord one can use a vibrator. The vibrations of the machine will excite the nerve endings in the glans of the penis and will elicit an erection via a reflex mechanism in the spinal chord (just like the knee-jerk reflex causes automatic contraction of the muscles in the leg). The 'erectile nerves' that run from the spinal chord to the penis will cause the inflow of blood to the erectile bodies to increase and the outflow to decrease, thus filling these bodies with blood and causing erection of the penis. If there is no sense of lust, the inflow of blood is too low or the nerves to the penis are damaged, then the erection will be limited or even non-existing.

**Reproduction**. In terms of evolution, erection has proven to be a good method to put male sperm into a womans womb. In ejaculation (*coming*) an amount of semen (prostatic fluid + sperm cells) is ejected into the urethra at the level of the prostate. The semen is propelled through the urethra by rapid muscular movements in its wall and ejected through the penis, on its way to the female egg-cell; to prevent the semen going the wrong way (to the bladder, which is closer by) the entry to the bladder is closed by a tiny sphincter at that very moment - that is the reason that ejaculation and urinating at the same time is impossible. Ejaculation is not called 'coming' for nothing: according to mother nature the goal is reached the very moment the semen came and erection is not needed any further.

---

# VI. Sperm

Sperm are ickle, in fact they are the icklest thing you'll find in a man's body (in comparison to the ovum, which is the largest cell in a woman's body). Measuring in at a tiny 5 microns long, approximately 300,000,000 - 400,000,000 begin their journey in the average ejaculation. Propelling themselves along by whipping and undulating their flagellum (the "tail"), they can achieve speeds of up to 6 iph (inches per hour!). They get their energy for this race from the semen in which they are discharged, which is made up of fructose, protein, citric acid, alkalines, and some other trace substances. Sperm only make up around 5% of the volume of semen, which incidentally contains more protein per ejaculation than a pork chop, and around 5 calories per teaspoonfull. Sperm can survive for a few days in the female body, to allow them time to reach their destination. They have receptor cells identical to those in the nose, which suggest they may "sniff" their way to the egg

Inside the testis are long, tortuous tubes known as the seminiferous tubules, shown in this scanning electron micrograph. There are over 200 of these tubules in the human testis and they represent the "factory" for the continual production of millions of from Antoni van Leuwenhoek to the Royal Society of London. He wrote that a "...middle-size grain of fine sand would contain at the least ten thousand."

This image shows a cross section through the many seminiferous tubules shown in the first figure. Inside each tubule are clusters of round cells that are immature sperm. As they mature and develop, they move towards the center hollow portion of the tube where they acquire tails.

A seminiferous tubule is cut open and shown at high magnification in this figure. The youngest, most immature sperm are located at the peripheral margin of the tubule and are called spermatogonia. These immature sperm either continually divide to renew the population of developing sperm or they mature to become sperm with tails. Mature sperm are situated in the center lumen of the tubule. Many long tails of mature sperm are seen in the center hollow portion of this tube.

**4.** Variants of Human Spermatozoa
1931

I

**How circumcision is done to an adult : our video presentation**

**Click here for Male Reproductive system video**

**----------**

---

# VII. INTERNAL ORGANS AND MALE REPRODUCTIVE SYSTEM

The TESTICLES are two oval-shaped glands which produce male hormones and sperm. It is normal for one testicle to hang lower in the scrotum than the other.

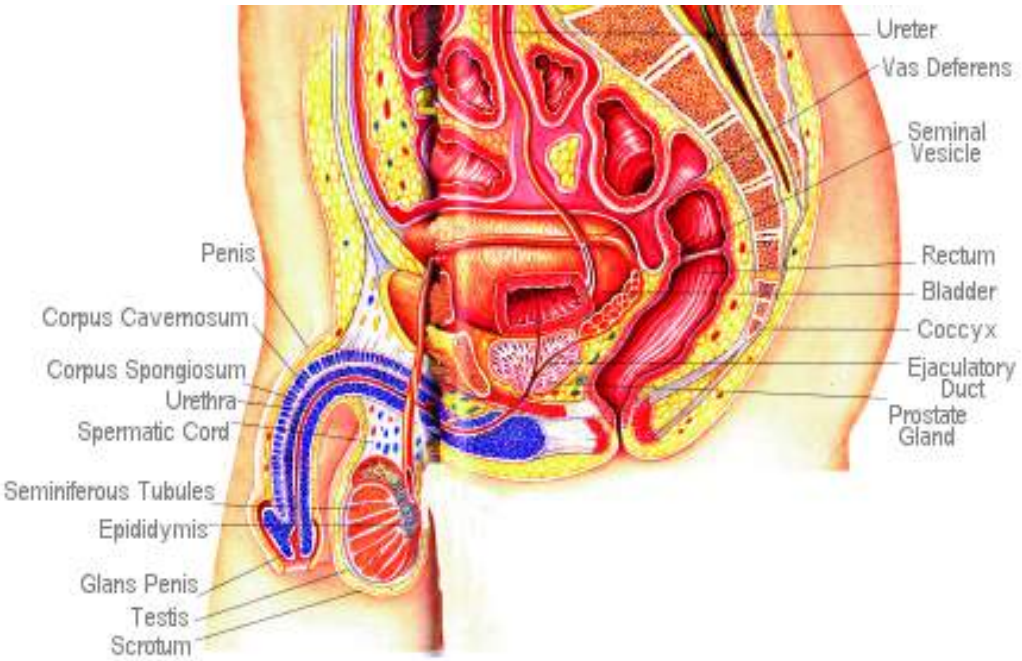


Each SPERMATIC CORD, or VAS DEFERENS is about 45 cm. long and passes from the groin over the bladder to form a storage place for sperm, the AMPULLA.

The SEMINAL VESICLE are glans that lie next to the ampulla where the sperm are stored. They secrete liquids important for the survival of sperm.

The PROSTATE is a chestnut-shaped gland placed just under the bladder which produces important substances for sperm survival. The stimulation of the prostate by the insertion of a penis or another object into the anus can cause a lot of pleasure. (Check out the section on the Prostate, and Prostate Cancer).

I

The URETHRA is a tube that goes from the bladder to the tip of the penis. In men, the urethra has two functions: urination and ejaculation. A muscle prevents urine from mixing with the semen during ejaculation.

A male continuously produces new sperm in the seminiferous tubules inside each of the two testicles from puberty until death. when sperm leave a testicle they enter one of the epididymis (a curved structure about one-half inch long located on the back side of each testicle). Inside each epididymis is a thin, tightly coiled tube (about 20 feet long!) where, as the sperm move through, they undergo a maturation process which gives them the ability to swim in a forward motion.

Then sperm enter one of the vas deferens. Each is a tube about 20 inches long which leads from one testicle, up into the body through the inguinal canal, loops around the bladder, and comes back down toward the inside end of the urethra. There it is attached by an ejaculatory duct to the urethra. It is at this interior end of the vas deferens that sperm collect and wait to be expelled out through the urethra at ejaculation.

On each side of the urehtra at the ejaculatory duct, each vas deferens joins with the opening of a seminal vesicle, and the seminal vesicles connect to the urethra. These seminal vesicles produce a fuild that is alkaline (important in overcoming the acidity of the vaginal secretions) and contains fructose (a type of sugar which is a nutrient for sperm).

Next, surrounding the urethra like a small doughnut, is the prostate gland. The prostate gland also produces an alkaline fuild, which flows at emission in the urethra through ducts near the ejaculatory ducts of the vas deferens and seminal vesicles. The prostate is also important in anal sex for men. When a penis (or other object) is inserted in to the man's anus, the object pushes against the prostate causing the pleasurable feeling experienced with anal sex among men.

Further down the urethra, nearer to where the penis leaves the body, is another pair of ducts. These lead to the two pea-sized Cowper's glands, which produce a mucus-like fluid.

During the time the sperm are traveling from the testicles to the ducts near the urethra they are moved along by cilia (small hair-like structures) and contractions of the tubes. Sperm do not begin to swim on their own until after ejaculation. This entire process from development of sperm in the testicle, maturation in the epididymis, and travel through the vas deferens takes about seventy days.

During male sexual arounsel, the Cowper's glands secrete their fluid, which lubricates the urethra. This can happen close to the time of actual ejaculation, so sperm may already be present in this clear pre-ejaculatory fluid. SO YOU CAN STILL GET YOUR PARTNER PREGNANT WITHOUT EJACULATING!

At ejaculation, the opening between the bladder and the inside end of the urethra closes. At the same time the sperm, fluid from the seminal vesicles, and fluid from the prostate gland mix together as semen and enter the urethra to be foreced out of the opening in the head of the penis by the muscle spasms of orgasm.

The total volume of semen in each ejaculate is around one teaspoon and contains 120 to 600 million sperm (somebody actually counted!). But even this enormous number of microscopic sperm is extremely small in volume, equivalent to less than a tiny drop of semen. All the rest of the semen is fluid from the prostate gland (about one-third), the seminal vesicles (about two-thirds) and other internal glands. This explans why the

I

volume of a man's ejaculate is not noticeably reduced after a vasectomy since only the sperm are missing.

The colour of semen varies, normally shades of white, yellow or gray. The texture is usualy creamy, sticky, and thick immediately after ejaculation. The semen then becomes more liquid but eventually dries after exposure to air.

Any time a man has difficulty urinating or ejaculating, or if semen changes, he should consult a urologist.

---

## VIII. What exactly is circumcision and what is it not

Infant circumcision is made more acceptable by believing the notion that there is a flap of skin at the end of the penis called the foreskin which hangs over the glans and circumcision simply removes that flap. This is factually incorrect. By thinking that the foreskin is separate or "extra" tissue it is easier to believe that its removal does little to impact or change the rest of the skin of the penis.

There is really no separate anatomical structure called the foreskin. Rather there is one single continuous skin sheath of the penis which is called the skin system. This single, uninterrupted skin sheath may, at any given time, fold to varying degrees over the glans or retract to reveal it. The amount of the skin system that is folded over can be referred to as the forefold of the skin system. Its extent changes often to accommodate degrees of erection, and it is never a separate structure from the skin of the shaft.

What the operation called circumcision actually does then is to interrupt and significantly reduce the skin system of the penis to a fraction of its normal anatomical and functional extent.

# The skin system of the penis

The intact penis is covered by one single continuous skin sheath or skin system. The skin sheath is partly folded at different times. This folded part of the skin system is called the foreskin or prepuce.

The fold of skin is often mistaken as a single layer, or a flap of skin. This is wrong. Instead, it is a free, two-layer fold that forms when the skin coming down the penis from the shaft folds underneath itself somewhere near the tip of the penis then travels back to an attachment point behind the glans (see figures 6 and 4). The two sides of the fold do not adhere to each other even though they lie flat against each other appearing to form a single flap of skin.

Also, in the adult the skin system does not adhere to the glans so it can unfold back off of the glans, leaving it fully exposed. When we speak of this skin sheath we are not talking about the surface of the glans itself in the same way that we talk about the surface of the shaft, because the glans has no real skin. When we talk about the skin covering of the glans, this can only mean the foreskin. The foreskin is its skin covering.

### The fictitious foreskin

I

A significant anatomical error has been made historically and continues today in describing the penis by delineating the "foreskin" as a separate anatomical structure from the shaft skin. People talk about the "foreskin" separately from the shaft skin. This is a mistake. It is not correct.

The foreskin is not a separate anatomical structure from the rest of the skin of the penis. This is actually an artificial separation. When the word foreskin is used, rather than referring to a separate part of the penis, it means the part of the continuous skin system which happens to be folded over the glans at any given time. So there is no real anatomical border to the "foreskin." Since the proportion of the skin system that is folded over the glans increases and decreases by folding and unfolding to various degrees all the time, we realize that "foreskin" is a poor way of describing the anatomy of the penis. Instead, more accurate terminology might be to describe that part of the skin system which covers the glans as the "forefold of the skin system."

Unlike the false border between "foreskin" and shaft skin, there is a real anatomical border which exists in the skin system. It is between the mucosal, or non-keratinized, part of the skin system (which consists of the inner lining of the foreskin along with the surface of the glans) and the keratinized part (which is the outer penile skin, including the outer foreskin). That border is at the most distal part, or tip, of the skin system - it is the tip of the forefold (see figures 6 and 7).

## The mobility of the skin system

The entire skin system moves freely. In the intact (uncircumcised) male, the penis has a low friction gliding plane immediately beneath the surface of the skin which is like no other body structure. This means that the skin of the penis does not adhere to the underlying tissue the way that skin adheres to other parts of the body. This unique quality allows the entire skin of the penis to move as a unit back and forth longitudinally or around the shaft circumferentially making it the most mobile skin in the intact male.

The skin system covers the head of the penis to varying degrees depending on moment-to-moment factors such as the state of erection and temperature. The free fold of the skin system which we call "foreskin" unfolds and re-folds constantly to varying degrees, adjusting to the current state of the penis. It is a very dynamic system. The foreskin, among other functions, provides the penis with a reservoir of skin which is needed during erection. The skin of the erect, intact penis is still mobile and loose, allowing the mucosal inner foreskin to roll back and forth over the glans (see figure 7).

Thus, the dividing line between what we call the skin of the shaft and foreskin is regularly crossed by the "shaft skin" or "foreskin." The delineated "foreskin" may become entirely "shaft skin" when the penis becomes more erect because it is now around the shaft. And if the penis shrinks momentarily beyond its usual flaccid state, perhaps due to a cold swim at the beach, some of the "shaft skin" is now "foreskin" because it covers the glans. The skin system is a dynamic, mobile and flexible skin sheath that moves and adjusts to the momentary needs of the penis (see figure 7). Such a system is not normally observed in the circumcised male.

Another anatomical error is committed in describing the foreskin as a flap of skin protruding from the shaft skin (figure 6a). This notion presumes that the foreskin is a single layer of skin, like the skin of the shaft, which grows from the shaft to cover the glans. In describing the foreskin this way it is easier to see it as redundant or "extra skin" and it is more difficult to see how removing it might impact the rest of the penis. This description of the foreskin is inaccurate. The foreskin is not "extra" skin which protrudes from the shaft.

There is no extra skin on the body - this is a silly notion. Instead, it is a free, double-layered fold - an integral part of the skin system. The foreskin extends from a point on the shaft behind the glans to cover the glans then folds back underneath itself to the same attachment point on the shaft, usually near the glans (see figure 6). The eyelid works much the same way. The eye lid is not a single flap of skin, but rather two freely moving layers of a fold of s kin, so that both the foreskin and the eyelid have two layers. That's why it is more appropriate to refer to the "foreskin" as the forefold of the skin system.

In reality then, infant circumcision does not remove the "tip of the penis" or "redundant skin" nor does it remove a separate structure called "the foreskin." Rather, infant circumcision deletes a significant percentage of the skin system of the penis, rendering the skin system relatively dysfunctional and rendering the penis less dynamic.

# The "triple whammy"

The circumcised penis loses sensitivity in three ways:

1. **Loss of the foreskin nerves themselves.** As has been demonstrated by studies such as the one by Dr. Taylor and by the testimonials of the majority of intact men, the inner foreskin possesses a greater density of nerve endings. It is thought to be more erogenous than even the glans. The is no question that the foreskin is a highly erogenous tissue. This tremendous amount of sensitivity is lost completely when the forefold of the skin system is amputated. In addition to this, the most sensitive part of the penis, the frenulum of the foreskin, is either partially or totally removed in most infant circumcisions. The frenulum is the continuation of the inner foreskin which attaches to the underside (ventral part) of the glans. Thus, a significant percentage, if not the majority, of erogenous nerve supply to the penis is removed in circumcision at birth.
2. **Damage to the glans.** The erogenous sensitivity that remains after circumcision is primarily in the glans. This is further reduced by removal of the protective foreskin which leaves the glans permanently exposed. Unlike the shaft of the penis, and most of the rest of the body, the head of the penis, does not posses its own attached skin. This structure, like the eye ball and the gums of the mouth, is a somewhat naked structure. Its surface is non-keratinized, like that of the gums, the eye ball, and the clitoris in women. That means that it does not posses a protective thick layer like the keratinized skin of the outer penile skin system. Like the gums and the eye ball, the glans of the intact penis has a retractible skin covering. The skin covering of the glans *is* the foreskin. The eyelid is very similar in architecture to the foreskin. If the eyelid were removed and the eyeball were to become keratinized, you'd have a much harder time seeing. The same is true of the glans. It becomes artificially keratinized (dry, ha rdened, discolored, and wrinkled) as a result of permanent exposure, and thus less sensitive. Because most American men are circumcised and have a glans of this nature, it is harder to notice the abnormality. But just compare the glans of an intact man with that of a circumcised man next to each other and you'll notice a big difference. Thus, in addition to removing lots of erogenous nerve endings in the inner foreskin and frenulum, circumcision further desensitizes the remaining sensitivity of the glans by leaving it exposed.
3. **Loss of skin mobility.** The nerve endings in the glans are predominantly complex touch receptors also known as mechanoreceptors. This is different from the light touch receptors of the skin which detect surface friction. The mechanorecptors are best stimulated by massage action rather than surface friction. Thus, the glans is best stimulated to feel pleasure by a rolling massage action. With an ample

and highly mobile skin system that rolls over the glans with pressure from the opposing surface, this optimal stimulation of the glans is achieved while avoiding direct friction of the delicate glans surface. Direct friction tends to fire off pain receptors causing irritation and also causes further keratinization of the glans. With the skin system of the penis significantly reduced by circumcision, the mobility is essentially gone and now the penis is a static mass with no dynamic self stimulation mechanism. Now, it must be rubbed. Direct friction is now the primary form of stimulation. So then circumcision further reduces erogenous s ensitivity in the penis by reducing skin mobility and thus the ability to use the foreskin to massage the glans. The combination of foreskin and glans in concert results in an even higher level of stimulation which is unknown to the circumcised male.

### Conclusion

Circumcision of an infant male significantly reduces erogenous pleasure potential in his penis when he becomes sexually active and continues to be reduced as he ages until, in many cases, he is left with relatively little sensation.

# Adult Circumcision vs. Infant Circumcision

A common misperception is that infant circumcision is preferable to adult circumcision because it spares a man pain and trauma. Many physicians however say the opposite and critics admit that most of their objections to infant circumcision cannot be applied to the adult procedure. Here's why:

1. **More precise with better outcome.** Circumcision of an adult can be more precise and less risky than for the infant. This is because the adult penis is fully formed. Many plastic surgeons operate on the penis in the erect state because this way it is clear to what extent the skin is stretched during erection. In the infant, this more precise method cannot be employed. Also, based on the knowledge of his own penis, the adult patient can specify how much tissue to remove, the infant cannot. In terms of how much tissue to remove, there is much more guess work involved in the infant and often too much skin is removed. In adult circumcision precise instruments are used. In the infant, usually more cumbersome and less precise instruments like the Gomco clamp are used. The results of operating on a fully formed penis, in the erect state, with precise instruments by a trained surgeon, benefit the adult and not the infant.
2. **Reduced risk of injury.** For the same reasons mentioned above, injury to the penis is less likely in adult circumcision than in infant circumcision. It is less likely that too much or too little tissue will be removed and the chances of lacerating the glans itself are also minimized. Scarring is also reduced in the adult.
3. **Reduced loss of sensitivity.** Because in the adult, the penis has had many years to develop with a foreskin covering, the glans is fully sensitive at the time of the circumcision. The glans has grown with its protective covering and the foreskin has already separated naturally from the glans. This spares the adult some of the sensitivity loss that occurs when circumcision is performed at birth. At birth, the foreskin must be torn away from the glans to which it is normally adhered. Then, the denuded glans of the infant spends much time exposed to caustic urine while in diapers. In adult circumcision this early damage to the glans is avoided.
4. **Personal choice.** With adult circumcision the patient is making a personal choice to have himself

circumcised. He has the option of comparing the pros and cons and has had the opportunity to know what having a foreskin is like. This eliminates the "lack of choice" objection made by critics. With elected adult circumcision, critics see no violation of rights.

5. **Reduced potential psychological effects.** With adult circumcision potential psychological effects are reduced. This is because the patient understands the experience. He knows why it is happening and that he has chosen this. Anesthesia is used in the adult and is usually omitted or ineffective in the infant. In contrast, the infant has an experience of inexplicable pain and terror which he cannot rationalize as an adult. Some speculate that this intensely painful experience for the infant can lead to problems later on. Although on the surface it may seem that an infant is less sensitive to or unaware of the circumcision experience, he does experience it fully and because of his very formative and psychologically sensitive age, the experience is thought to be potentially more impacting than it is for the adult.

Even though the facts do not support the claim that adult circumcision is "worse" than infant circumcision, some pro-circumcision advocates contend that adult circumcision is painful, traumatic and dangerous, and that for this reason most adult men who are intact choose to remain uncircumcised. But when intact men are asked about the idea of being circumcised, most say that they have no desire to give up this part of their body - there is no reason to even consider it. Their foreskin gives them no more trouble than their eyelids, lips or testicles. Instead it affords them pleasure and comfort. Anti-circumcision advocates say that it is ridiculous to presume that the idea would even cross an uncircumcised man's mind. To them, it is the same as asking why intact women don't think about having the clitoral foreskin removed.

---

## Microspic Pictures of Male's Sex Organs - Link page

Visit this web-page in internet for viewing detailed pictures and explanations of each microspic parts of male's sexual organs for which CLICK HERE.

----------End----------